



Case Report

Osseous Metaplasia of the Gallbladder: Report of Two Cases

Semra Dogan,¹ Asiye Safak Bulut²

¹Department of General Surgery, TOBB University of Economics and Technology Faculty of Medicine, Ankara, Turkey

²Department of Pathology, TOBB University of Economics and Technology Faculty of Medicine, Ankara, Turkey

Abstract

Osseous metaplasia is rarely seen in the gastrointestinal tract. Its occurrence in the gallbladder is even more rare; only 7 cases have been reported thus far. Two additional cases are described herein: one was an incidental finding and the other simulated an intramural gallstone in a chronically inflamed, calculi-containing gallbladder. The patients were a 32-year-old man and a 52-year-old man who presented with abdominal pain. Ultrasonography revealed small gallstones in 1 patient. Laparoscopic cholecystectomies were performed and histologies were consistent with chronic cholecystitis and cholelithiasis with intramucosal bone formations. One of the patients also had an adenomyoma in the fundus. Osseous metaplasia of the gallbladder is a rare event. It is mostly incidental and although its etiology and clinical significance are unknown, it may mimic a gallstone, which could affect treatment options. The pathogenesis could be osteogenic stimulation as a result of the inflammatory process.

Keywords: Bone metaplasia, gallbladder, heterotopic bone, heterotopic ossification, osseous metaplasia

Cite This Article: Dogan S, Bulut A. Osseous Metaplasia of the Gallbladder: Report of Two Cases. EJMO. 2017; 1(2): 108-110

Osseous metaplasia, which is also known as heterotopic bone, heterotopic ossification, bone metaplasia, is rarely reported in gallbladder and its clinical significance is unknown. The exact mechanism of bone formation in the various parts of the body is not clear but it can be related with some conditions like phleboliths, benign neoplasm and malignancies, epithelial tissues of gastric mucosa, seminal vesicle mucosa, osteoinduction by chronic inflammation and postoperative abdominal scars.^[1] Stromal fibroblastic proliferation, chronic and active inflammation may play a role in its formation in the gallbladder mucosa. Here we report two cases with the review of the literature.

Case Report

Case I

A 37-year-old male presented to the department of internal medicine with right upper quadrant pain continuing for 5 days. He was afebrile at presentation, with stable vital signs. Physical examination demonstrated a positive Murphy sign. Laboratory findings were unremarkable for whole blood count, liver function tests, sedimentation, ASO and CRP. Ultrasonography revealed small gallbladder stones. A laparoscopic cholecystectomy was performed with an uneventful postoperative course. The excised gallbladder measured 7 x 2.5 x 2 cm with three black intraluminal

Address for correspondence: Semra Dogan, MD. TOBB Ekonomi ve Teknoloji Universitesi Tıp Fakültesi, Genel Cerrahi Kliniği, Ankara, Turkey

Phone: +90 312 292 40 00 **E-mail:** opdrsemradogan@yahoo.com

Submitted Date: June 23, 2017 **Accepted Date:** August 22, 2017 **Available Online Date:** August 26, 2017

©Copyright 2017 by Eurasian Journal of Medicine and Oncology - Available online at www.ejmo.org



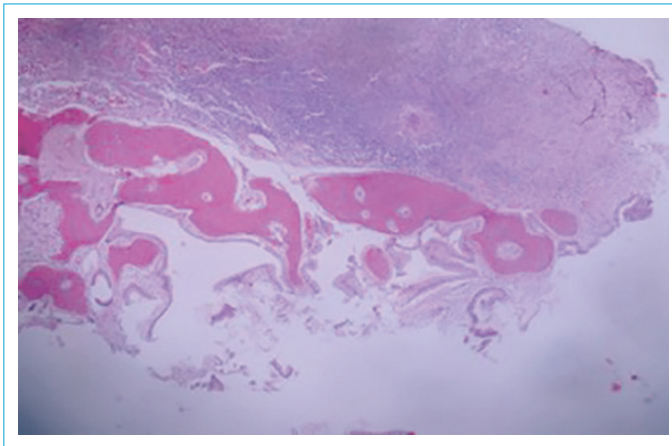


Figure 1. Heterotopic bone in the gallbladder mucosa with severe inflammation in the wall (HE, original magnification is x40).

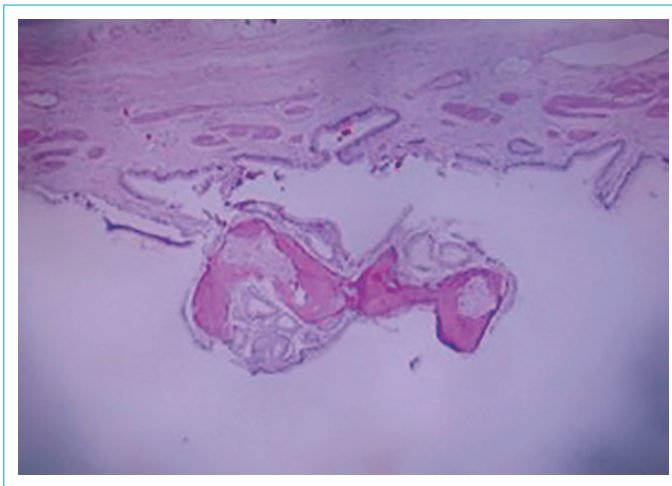


Figure 2. Heterotopic bone forming a small polypoid mass found incidentally in a mildly inflamed gallbladder (HE, original magnification is x40).

calculi, a 8-mm nodular lesion in the fundus and a 6-mm bone-like hard mass embedded in the mucosa, giving the impression of an intramural gallstone. Histologic diagnosis was chronic cholecystitis with cholelithiasis, adenomyoma and mucosal metaplastic bone formation (Fig. 1).

Case 2

A 52-year-old male, with a history of hypertension, venous insufficiency and a previous operation of tonsillectomy, presented with abdominal pain to the department of gastroenterology. He was afebrile at presentation. Physical examination demonstrated a slight abdominal distention. There were no abnormality in laboratory findings. No calculi was detected with ultrasonography. A laparoscopic cholecystectomy was performed with an uneventful postoperative course. The excised gallbladder measured 8 x 3.5 x 3.5 cm with a 3-mm intraluminal cal-

culus. Histologic diagnosis was chronic cholecystitis with cholelithiasis and metaplastic bone formation as an incidental finding (Fig. 2).

Discussion

Epithelial metaplasia is a common finding in the gastrointestinal tract. Gallbladders that contain gallstones or reveal features of chronic cholecystitis may exhibit pyloric gland metaplasia or intestinal metaplasia as a manifestation of chronic injury.^[2] However, mesenchymal metaplasia, particularly osseous metaplasia, is a rare and incidental finding in the gastrointestinal tract and it is extremely rare in the gallbladder. In the literature review, we determined seven reported cases so far.^[3-9] Although Yosepovich et al. described their case as the first one in the literature, there were two previous cases reported by Indyk et al. and Ortiz-Hidalgo et al. in 1957 and 2000, respectively.^[3-5] Since then, four more cases had been reported.^[6-9] All the cases were adult patients except for the Rege et al's case who was a 7-year-old boy with sickle cell disease.^[8] The metaplasia was associated with benign conditions like chronic cholecystitis,^[5, 8] a cholesterol polyp^[4] and a fasciitis-like fibrous proliferation [8] in these cases. There are also two metastatic gallbladder carcinomas showing stromal osseous metaplasia reported in the literature.^[10, 11] In Micseh et al's case, both the primary tumor and the metastasis showed stromal osseous metaplasia. But these two cases are somewhat different from the others and our's that ossification was in tumor's stroma. Our cases are associated with chronic cholecystitis and they showed similarities with the previous seven case.

Other gastrointestinal system pathologies may also show osseous metaplasia. In the latest review done by Montalvo et al. in 2012, Barrett's esophagus; hyperplastic polyp, carcinoid tumor and adenocarcinoma of the stomach; Peutz-Jagher's syndrome and adenocarcinoma of the small intestine; mucocele, mucinous cystadenocarcinoma and adenocarcinoma of the cecal appendix; hyperplastic, juvenile, tubular, tubulovillous and serrated adenomas, adenocarcinomas and adenoacanthoma of colon and rectum; and also proctocolitis and solitary ulcer syndrome may show osseous metaplasias.^[12]

The pathogenesis is unknown but the function of the gallbladder epithelium as an osteogenic stimulus was presented by Huggins et al. in an experimental study in 1933.^[13] In their study, they showed that the gallbladder epithelium is capable of inducing bone formation in the dogs and guinea pigs. There were two possible components in the tissue reaction that produces bone; namely, (a) epithelium and (b) certain kinds of connective tissue.

The connective tissue adjacent to the epithelium of the gallbladder do not normally form bone. These cells are identical in morphologic and tinctorial reactions with the fibroblasts of the abdominal wall which readily become osteogenic under the stimulus of these epithelia. Their concept derived from the evidence obtained in their experiments that bone is not an unusual, bizarre response to the adjacent, geographically abnormal epithelium, but that it is a normal and usual reaction of certain connective tissues. Thus the evidence showed that it is the subepithelial connective tissue which fails to respond to the osteogenic stimulus of the overlying epithelium and thus prevents the formation of an osseous layer in the gallbladder under normal circumstances. They stated that osteoblast is derived by metaplasia of certain connective tissue cells. In summary they said that, proliferating gallbladder epithelium is capable of stimulating bone formation in certain connective tissues such as abdominal wall. Other connective tissue areas such as the subepithelial connective tissue of the gallbladder and urinary bladder do not share in this tissue reaction and resist the bone stimulus of the epithelium. The formation of bone in these circumstances is thus biphasic.

The hypothesis proposed by Rhone and Horowitz in 1976 postulated the metaplasia of a pluripotent cell into an osteoblast under the influence of factors generated by epithelial cells and this seems a conclusive explanation of the induction mechanism of ossification.^[14]

In conclusion, we reported two rare cases of osseous metaplasia in the gallbladder mucosa. Although it is a non-specific finding and it doesn't cause clinical symptoms, it may be confused with a gallstone and may effect treatment op-

tions. Persistent inflammation may be the etiopathogenetic mechanism in such cases.

Disclosures

Peer-review: Externally peer-reviewed.

Conflict of Interest: None declared.

References

1. Vigorita VJ. Orthopaedic Pathology. New York: Lippincott Williams and Wilkins; 1999. p. 60.
2. Rosai J. Gallbladder and extrahepatic bile ducts. In: Rosai J, editor. Rosai and Ackerman's Surgical Pathology. 9th ed. Mosby; 2004. p. 1041.
3. Indyk J, Shipton EA. Heterotopic bone formation in the gall-bladder. *Med J Aust* 1957;44:9–11.
4. Ortiz-Hidalgo C, Baquera-Heredia J. Osseous metaplasia in polypoid cholesterosis. *Am J Surg Pathol* 2000;24:895. [\[CrossRef\]](#)
5. Yosepovich A, Nass D, Zagatsky M, Kopolovic J. Chronic cholecystitis with bone metaplasia. A case report. *Pathol Res Pract* 2002;198:765–6. [\[CrossRef\]](#)
6. Nelson JJ, Kahn AG. A case of bone metaplasia of the gallbladder epithelium. *South Med J* 2009;102:322–4. [\[CrossRef\]](#)
7. Lin MY, Shikle JF. To pick a 'bone' with the gallbladder. *South Med J* 2009;102:773–4. [\[CrossRef\]](#)
8. Rege TA, Vargas SO. Cholecystitis and cholelithiasis associated with an intramural fasciitis-like proliferation and osseous metaplasia. *Pediatr Dev Pathol* 2011;14:80–3. [\[CrossRef\]](#)
9. Il'chenko AA, Orlova IuN, Khomeriki SG. Bone metaplasia in the gallbladder wall. *Eksp Klin Gastroenterol* 2011:86–90.
10. Micseh G. Knochenbildung im Gallenblasenkrebs und in seinen Metastasen. *Frankfurt Z Path* 1933;44:430–8.
11. Cavazza A, De Marco L, Asioli S, Pastore L, Gardini G. Stromal osseous metaplasia in metastatic adenocarcinoma of the gallbladder. *Tumori* 1999;85:133–4.